

General Criteria for Gender Affirming Surgery (WPATH SOC8)

- a. Gender incongruence is marked and sustained
- b. Meets diagnostic criteria for gender incongruence prior to surgery
- c. Demonstrates capacity to consent for the specific gender-affirming surgery
- e. Other possible causes of apparent gender incongruence have been identified and excluded
- f. Mental health and physical conditions that could negatively impact the outcome of gender-affirming surgery have been assessed, with risks and benefits have been discussed
- g. Stable on their gender affirming hormonal treatment regime (which may include at least 6 months of hormone treatment or a longer period if required to achieve the desired surgical result, unless hormone therapy is either not desired or is medically contraindicated).

Documentation Requirements/ Letters of Support for Coverage of Surgical Facial Feminization Procedures

Gender affirming procedures shall be covered for an individual who is eighteen (18) years of age or older and has letters from two qualified New York State licensed health professionals who have independently assessed the individual and are recommending the individual for the surgery

One of these letters must be from a psychiatrist, psychologist, nurse practitioner, psychiatric nurse practitioner, or licensed clinical social worker with whom the member has an established and ongoing relationship.

The other letter may be from a psychiatrist, psychologist, nurse practitioner, physician, psychiatric nurse practitioner, or licensed clinical social worker acting within the scope of his or her practice, who has only had an evaluative role with the member.

The totality of the referral letters together must establish the following and must be written within 12 months at the time of surgery request:

- Member has persistent and well-documented gender dysphoria;
- Has received hormone therapy appropriate to the member's gender goals, which shall be for a minimum of twelve (12) months in the case of an member seeking genital surgery, unless such therapy is medically contraindicated or the member is otherwise unable to take hormones;
- Hormone therapy is necessary if it is appropriate to the member's gender goals recommended by the member's treating provider, clinically appropriate for the type of surgery requested, not medically contraindicated, and the member is otherwise able to take hormones. Ref 18 NYCRR 505.2(l)(2); (3)(i)(b);
- Has lived for twelve (12) months in a gender role congruent with the member's gender identity, and has received mental health counseling, as deemed medically necessary, during that time; there is no requirement that mental health counseling be provided continuously for twelve (12) months prior to surgery. [Ref 18 NYCRR 505.2(l)(3)(i)(c)]
- Has no other significant medical or mental health conditions that would be a contraindication to gender affirmation surgery, or if so, that those are reasonably well controlled prior to surgery;
- Has the capacity to make a fully informed decision and to consent to the treatment.

Covered Surgical Procedures for Facial Feminization

The following surgical procedures are considered covered benefits for members that meet general criteria for gender affirming surgery and possess all the required documentation outlined above

- Forehead and Supraorbital Bossing Reduction, Upper Third Feminization
 - Surgical Techniques:
 - Frontal sinus setback
 - Forehead contouring/shaving
 - Browlift with/without hairline advancement
 - Orbital contouring/shaving
- Cheek Augmentation
 - Surgical Techniques:
 - Fat grafting
 - Implants
 - Bone grafts
- Nose Feminization
 - Surgical Techniques:
 - Rhinoplasty/Septoplasty
- Lip Feminization
 - Surgical Techniques (*see feminizing fillers for non-surgical option*)
 - Lip lift
 - Lip implants
 - Fat grafting
- Jaw and Chin Feminization, Lower Third Feminization
 - Surgical Techniques:
 - Mandible reduction/osteotomy/contouring
 - Mandibular angle osteotomy/reduction
 - Chin Contouring with/without Genioplasty
- Removal of Laryngeal Prominence (Adam's Apple)/Neck Feminizations
 - Surgical Techniques:
 - Tracheal shave

Surgical Procedures Reviewed for Medical Necessity

The following surgeries are not usually considered treatments for gender dysphoria, but will be reviewed for medical necessity as in rare circumstances they may be necessary to treat issues secondary to silicone injections and other procedures done by unlicensed providers. Please note that anti-aging, skin laxity, and jowling are not acceptable indications and these procedures will not be considered medically necessary in those circumstances

- Meloplasty (Face Lift)
- Platysmaplasty (Neck Lift)
- Fat grafting to areas other than the cheek(s) or lip(s)

The following surgical procedures are not considered treatments for gender dysphoria. All procedures are reviewed for medical necessity, but these procedures are rarely to never considered medically necessary for the treatment of gender dysphoria as they are either masculinizing treatments; body dysmorphia treatments; and/or anti-aging treatments

- Blepharoplasty
- Lateral Canthopexy/Canthoplasty
- Face, submental, or neck liposuction
- Otoplasty
- Mandibular angle augmentation

How are Covered Surgical Procedures Determined?

Covered surgical procedures are based on accepted standards of care. Facial feminization surgery has been shown in research to be safe and effective at improving the quality of life and mental health of transfeminine people (Caprini 2023, Chou 2022, Morrison 2016, Morrison 2020, Rosales 2023).

Surgical facial feminization procedures are not cosmetic (Dubov 2018), and the goals of each procedure are well defined. Study of the sex-based differences between the skulls and soft tissue structures of male-sex and female-sex skeletons/bodies provides the basis of surgical procedures to feminize the face. These key difference or surgical-target areas have been well characterized in literature (Altman 2012, Barnett 2023, Becking 2007, Somenek 2018, Sykes 2020, Telang 2020).

This table (De Boulle 2021) provides a summary of the sex-based differences between male-sex and female-sex faces. It is important not to conflate sex with gender identity.

Female-Sex Face	Male-Sex Face
Large, smooth forehead with some convexity and arched eyebrows	Wider forehead with horizontal brow and prominent supraorbital ridge
Eyes that appear wide open	Deeper-set eyes that appear close together
Proportionally smaller, narrow nose with upturned nasal top	Proportionally larger, wider, and more projected nose
Obtuse nasofrontal angle	Less obtuse nasofrontal angle
Obtuse nasolabial angle	Less obtuse nasolabial angle
Heart-shaped taper in lower face with smaller lower-to-upper face ratio	More equal ration of lower-to-upper face proportions
Prominent, full cheeks and cheekbones	Squared lower face and jaw
Full lips, especially anteroposterior axis	Wider mouth with thinner lips
Rounded, narrow, proportionally short chin	Long, square, flat chin

(De Boulle 2021)

This image (Asokan 2023) highlights sex-based differences on digital renderings of the human skull.

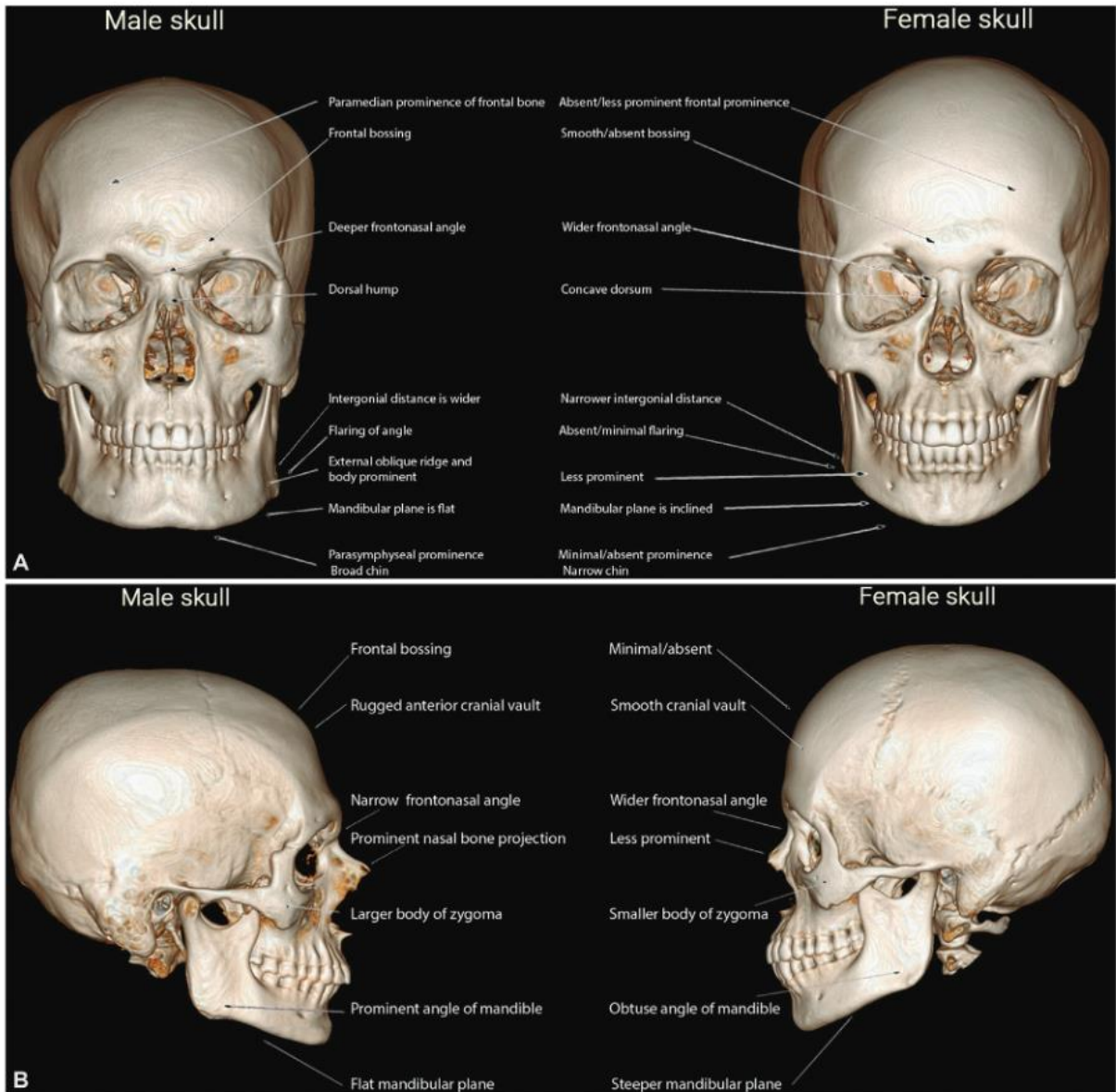


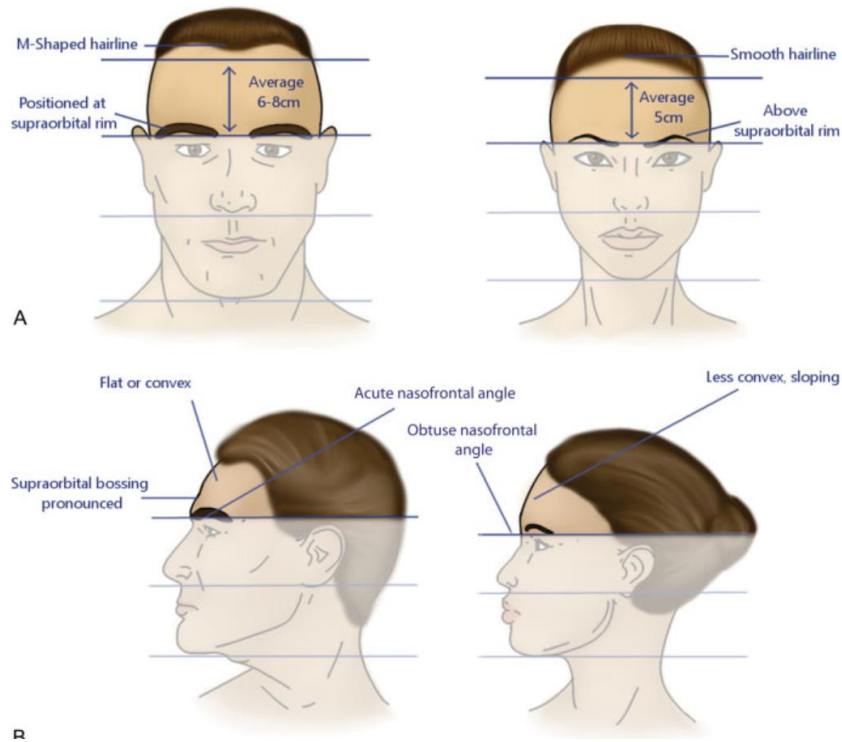
Fig. 1 Key skeletal differences in male and female skulls.

(Asokan 2023 - Image)

Target areas of the face can be organized by vertical location or dividing the face into three parts: the upper face, middle face, and lower face.

Upper Third:

In the upper third of the face, the forehead represents an important target area (Bonapace-Potvin 2023, Wulu 2023).

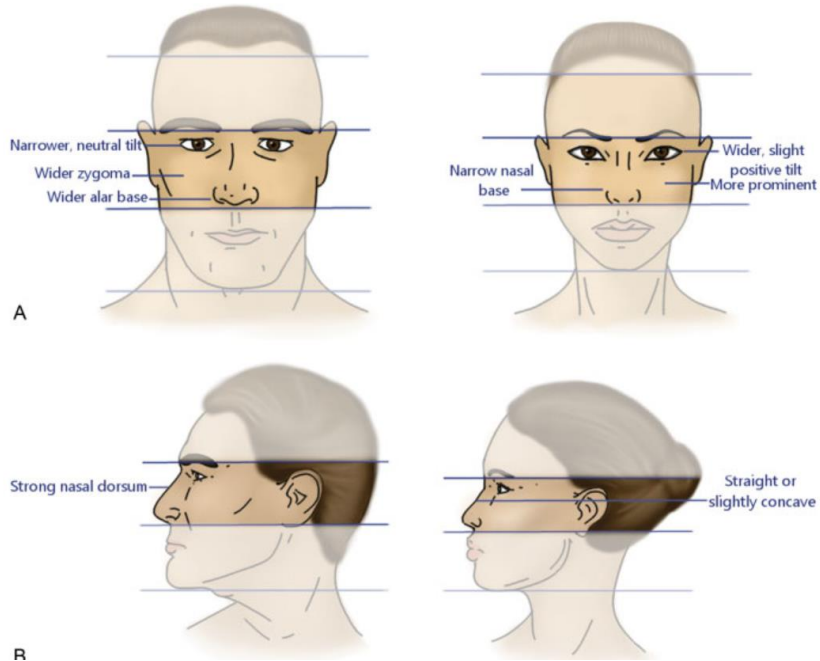


(Somenek 2018 – Image)

Surgically, the goal is to flatten the forehead and reduce the prominent brow ridge or frontal bossing. Feminization of the forehead via frontal-sinus setback and contouring/shaving of the brow ridge is safe and effective, and one of the most common feminizing surgical procedures for the face (Chaya 2021, Eggerstedt 2020). While many techniques have been documented, an ideal or uniform technique has not been established (Altman 2018, Di Maggio 2019, Pansritum 2021, Spiegel 2011). Brow lift, which is a manipulation of the soft tissue of the upper third of the face, is often performed at the same time as forehead and frontal bossing reduction, and creates a feminizing widening effect of the eyes and upper face.

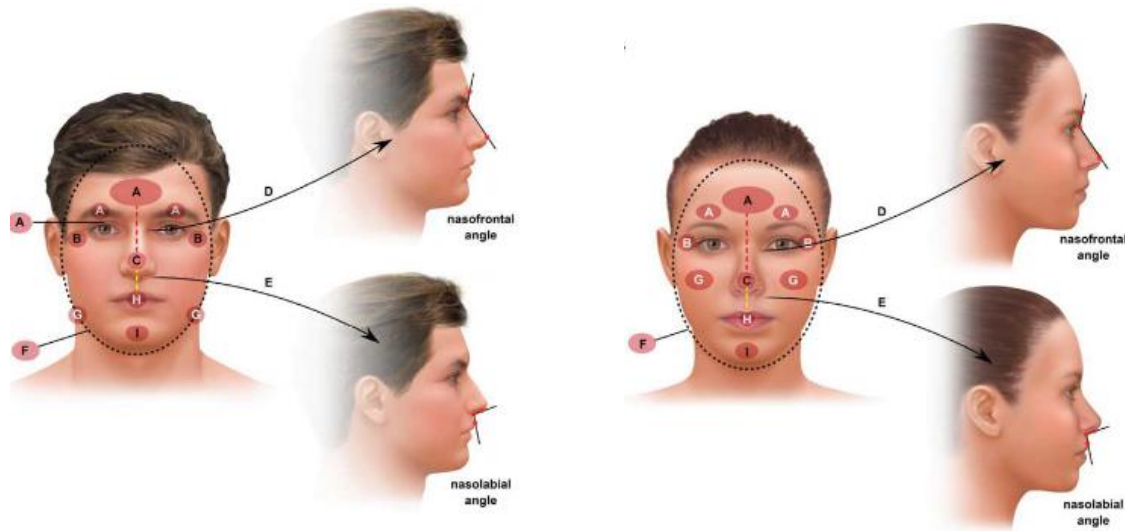
Middle Third:

Surgical feminization of the middle third of the face includes rhinoplasty and cheek augmentation.



(Somenek 2018 - Image)

Noses of the female sex have a different angle in relation to the forehead and lip, and often have a convexity.



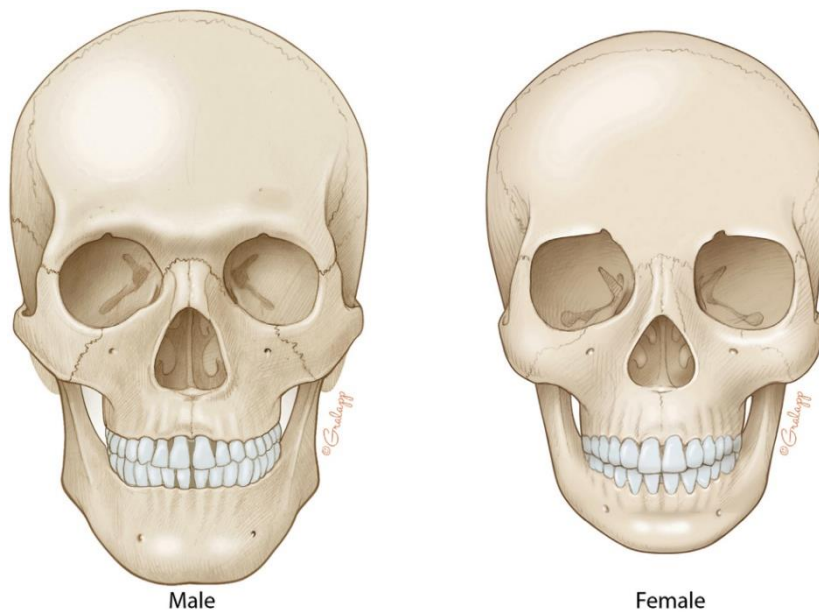
(De Boulle 2021 – Image)

Feminizing rhinoplasty often involves general reduction in the size of the nose, and reconstruction to change the nasofrontal and nasolabial angles (Báez-Márquez 2022, Jacobs 2023).

Female-sex skulls also have larger more prominent zygomatics or cheek bones, and female-sex faces have fuller cheeks in part due to the soft tissue. The cheeks can be augmented surgically using techniques such as implants, fat grafting, or bone grafting (Swonke 2023, Weinstein 2023, Whitehead 2019). What technique is utilized should be based off member preference, the surgeon's experience, and indication based on the pros and cons of each method in regard to a specific member.

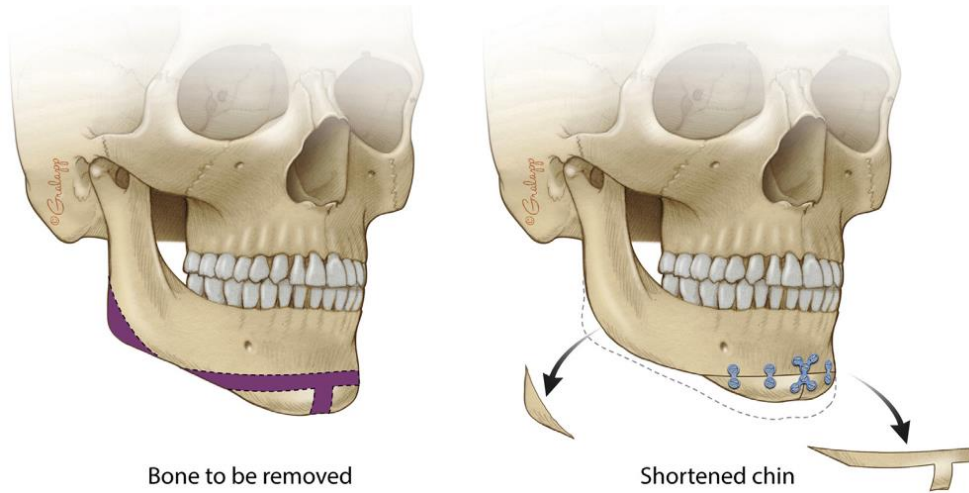
Lower Third:

Feminization of the lower face involves reduction of the mandibular angle and softening of the chin via reduction of chin width and alteration of chin projection.

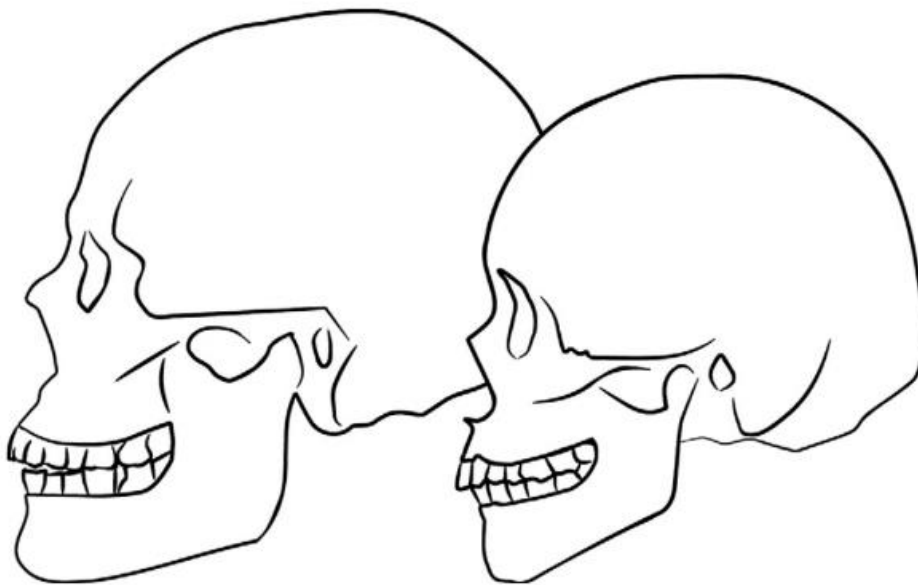


(Deschamps-Braly 2019 - Image) Note the projection of the mandibular angle of the male-sex skull as well as the wide, square chin versus the rounded female-sex jawline.

To surgically feminize the mandible, bone is simply removed from the mandibular angle at the back of the jaw. To feminize the chin, different surgical techniques can be employed to reduce the width, while also changing the projection, generally creating a more pointed appearance (Boucher 2017, Deschamps-Braly 2019, Glorion 2022, Khetpal 2023).



(Deschamps-Braly 2019 - Image) Note that the chin osteoplasty also creates a steeper downward slope in the angle of the jawline.



(Altman 2012 - Image) In this image the difference between the slope of the female-sex versus male-sex jawline is more apparent in full profile.

Guidance: Body Dysmorphia and Gender Dysphoria

As part of the evaluation for medical necessity of gender affirming procedures, body dysmorphia must be excluded. The DSM5 defines body dysmorphia by four criteria, listed below

- (1) Preoccupation with one or more perceived defects or flaws in physical appearance that are not observable or appear slight to others.
- (2) At some point during the course of the disorder, the individual has performed repetitive behaviors (e.g., mirror checking, excessive grooming, skin picking, reassurance seeking) or mental acts (e.g., comparing his or her appearance with that of others) in response to the appearance concerns.
- (3) The preoccupation causes clinically significant distress or impairment in social, occupational or other areas of functioning.
- (4) The appearance preoccupation is not better explained by concerns with body fat or weight in an individual whose symptoms meet diagnostic criteria for an eating disorder.

Letters of support from behavioral health providers should assess for, and exclude, body dysmorphia. Untreated body dysmorphia can worsen mental health and pose unique health risks during the surgical gender affirmation process.

Criteria for Coverage of Surgical Revision of Prior Facial Feminization Procedures

Requests for surgical revisions will be reviewed on a case-by-case basis. Surgical revision requests that do not meet all of the below requirements are not considered medically necessary

- Detailed history all prior facial procedure(s) including operative reports, the intended result, and any complications experienced during the procedure(s)
- Documented recent physical exam performed by the operating surgeon with a detailed assessment of the current state of feature or area proposed to be revised surgically, including:

- Clear commentary on whether prior procedures produced a feminizing change versus pre-procedure. **Descriptions of feminizing results are described in detail in above guidance*
 - Body dysmorphia as an alternate cause of distress related to a feature or area must be excluded in letters of support **See body dysmorphia definition in above guidance*
- OR clear description of a functional complication secondary to a prior procedure such as implant infection, breathing problems/sinus defects, and chewing abnormalities
 - If the revision is of an area altered by procedures performed outside of formal medical settings (e.g. silicone injections), past procedures as well as related sequelae are documented along with surgical treatment plan
- If the revision is to fix breathing problems after rhinoplasty/septoplasty, documentation demonstrates that an ENT has been consulted; is guiding the surgical plan; determined if additional surgery is appropriate; and recommended what specialist (e.g. plastics vs ENT) is best suited for the revision
- If revision of boney structures is planned, a completed CT scan is included in the documentation, and the surgical plan discusses any existing hardware found and how this may affect the surgical plan
- Documentation of discussion of treatment options and prognosis with the member including:
 - Discussion of the estimated success rate of the requested revision procedure and risks and benefits of repeat surgery
 - If hardware removal is planned, discussion of the specific risks and benefits and complexity of hardware removal/replacement
- If staged revision or multiple procedures are planned, **they must be noted in the initial request** and justification for why the procedures are staged must be documented
- For fat grafting procedures, justification of the volume of fat, or number of CCs referencing standards of care or literature. **Oversized volume requests or requests without justification will be voided*

CPT Code Guidance

**Please see separate coding guidance document for gender affirming surgeries*

References:

1. Alper DP, Almeida MN, Hu KG, et al. Quantifying Facial Feminization Surgery's Impact: Focus on Patient Facial Satisfaction. *Plast Reconstr Surg Glob Open*. 2023;11(11):e5366. doi:10.1097/GOX.0000000000005366
2. Altman K. Facial feminization surgery: current state of the art. *International Journal of Oral and Maxillofacial Surgery*. 2012;41(8):885-894. doi:10.1016/j.ijom.2012.04.024
3. Altman K. Forehead reduction and orbital contouring in facial feminisation surgery for transgender females. *British Journal of Oral and Maxillofacial Surgery*. 2018;56(3):192-197. doi:10.1016/j.bjoms.2018.01.009
4. Asokan A, Sudheendran MK, Mohandas M, George PS, Nair RM. Facial Feminization Surgery: Preoperative Planning and Surgical Technique for a Harmonious Outcome. *Indian J Plast Surg*. 2023;56(4):298-309. doi:10.1055/s-0042-1759692
5. Bachelet JT, Souchere B, Mojallal A, Gleizal A, Boucher F. Chirurgie de féminisation du visage – tiers supérieur. *Annales de Chirurgie Plastique Esthétique*. 2016;61(6):877-881. doi:10.1016/j.anplas.2016.07.019
6. Báez-Márquez J. Feminization Rhinoplasty. *Otolaryngologic Clinics of North America*. 2022;55(4):809-823. doi:10.1016/j.otc.2022.04.005
7. Barnett SL, Choe J, Aiello C, Bradley JP. Facial Feminization Surgery: Anatomical Differences, Preoperative Planning, Techniques, and Ethical Considerations. *Medicina (Kaunas)*. 2023;59(12):2070. doi:10.3390/medicina59122070
8. Becking AG, Tuinzing DB, Hage JJ, Gooren LJG. Transgender Feminization of the Facial Skeleton. *Clinics in Plastic Surgery*. 2007;34(3):557-564. doi:10.1016/j.cps.2007.04.009
9. Bonapace-Potvin M, Pepin M, Navals P, Medor MC, Lorange E, Bensimon É. Facial Gender-Affirming Surgery: Frontal Bossing Surgical Techniques, Outcomes and Safety. *Aesth Plast Surg*. 2023;47(4):1353-1361. doi:10.1007/s00266-022-03180-3
10. Boucher F, Gleizal A, Mojallal A, Bachelet JT. Chirurgie de féminisation du visage – tiers moyen et inférieur. *Annales de Chirurgie Plastique Esthétique*. 2017;62(2):122-130. doi:10.1016/j.anplas.2016.12.003
11. Caprini RM, Oberoi MK, Dejam D, et al. Effect of Gender-affirming Facial Feminization Surgery on Psychosocial Outcomes. *Ann Surg*. 2023;277(5):e1184-e1190. doi:10.1097/SLA.0000000000005472

12. Chaya BF, Berman ZP, Boczar D, et al. Current Trends in Facial Feminization Surgery: An Assessment of Safety and Style. *J Craniofac Surg.* 2021;32(7):2366-2369. doi:10.1097/SCS.00000000000007785
13. Choe J, Parikh S, Barnett SL, Sam S, Chen K, Bradley JP. Facial Feminization Surgery Review: Diagnosis, Preoperative Planning, Surgical Techniques, and Outcomes. *FACE.* 2021;2(4):426-435. doi:10.1177/273250162111057299
14. Chou DW, Bruss D, Tejani N, Brandstetter K, Kleinberger A, Shih C. Quality of Life Outcomes After Facial Feminization Surgery. *Facial Plast Surg Aesthet Med.* 2022;24(S2):S44-S46. doi:10.1089/fpsam.2021.0373
15. Coon D, Berli J, Oles N, et al. Facial Gender Surgery: Systematic Review and Evidence-Based Consensus Guidelines from the International Facial Gender Symposium. *Plastic & Reconstructive Surgery.* 2022;149(1):212-224. doi:10.1097/PRS.00000000000008668
16. Dang BN, Hu AC, Bertrand AA, et al. Evaluation and treatment of facial feminization surgery: part I. forehead, orbits, eyebrows, eyes, and nose. *Arch Plast Surg.* 2021;48(5):503-510. doi:10.5999/aps.2021.00199
17. Dang BN, Hu AC, Bertrand AA, et al. Evaluation and treatment of facial feminization surgery: part II. lips, midface, mandible, chin, and laryngeal prominence. *Arch Plast Surg.* 2022;49(1):5-11. doi:10.5999/aps.2021.01956
18. De Boulle K, Furuyama N, Heydenrych I, et al. Considerations for the Use of Minimally Invasive Aesthetic Procedures for Facial Remodeling in Transgender Individuals. *Clin Cosmet Investig Dermatol.* 2021;14:513-525. doi:10.2147/CCID.S304032
19. Deschamps-Braly J. Feminization of the Chin: Genioplasty Using Osteotomies. *Facial Plastic Surgery Clinics of North America.* 2019;27(2):243-250. doi:10.1016/j.fsc.2019.01.002
20. Di Maggio M. Forehead and Orbital Rim Remodeling. *Facial Plastic Surgery Clinics of North America.* 2019;27(2):207-220. doi:10.1016/j.fsc.2019.01.007
21. Dubov A, Fraenkel L. Facial Feminization Surgery: The Ethics of Gatekeeping in Transgender Health. *Am J Bioeth.* 2018;18(12):3-9. doi:10.1080/15265161.2018.1531159
22. Garcia-Rodriguez L, Thain LM, Spiegel JH. Scalp advancement for transgender women: Closing the gap. *The Laryngoscope.* 2020;130(6):1431-1435. doi:10.1002/lary.28370
23. Glorion A, Perrillat A, Foletti JM, Cristofari S. Surgical techniques used in chin feminization: Literature review and knowledge update. *Journal of Stomatology, Oral and Maxillofacial Surgery.* 2022;123(6):e883-e887. doi:10.1016/j.jormas.2022.07.015
24. Jacobs J, Johnson CZ, Loyo M. Feminization rhinoplasty. *Operative Techniques in Otolaryngology-Head and Neck Surgery.* 2023;34(1):38-45. doi:10.1016/j.otot.2023.01.006
25. Khetpal S, Baker NF, Hu V, et al. Feminizing Genioplasty: A Review of Operative Techniques and Clinical Outcomes. *FACE.* 2023;4(2):207-217. doi:10.1177/27325016231164152
26. Lundgren KC, Koudstaal MJ. Midfacial Bony Remodeling. *Facial Plastic Surgery Clinics of North America.* 2019;27(2):221-226. doi:10.1016/j.fsc.2018.12.004

27. Michael, Eggerstedt Young, Soo Hong Connor J, Wakefield Jennifer Westrick • Ryan M. Smith1 • Peter C. Revenaugh1. Setbacks in Forehead Feminization Cranioplasty: A Systematic Review of Complications and Patient-Reported Outcomes | Aesthetic Plastic Surgery. Accessed January 11, 2024. <https://link.springer.com/article/10.1007/s00266-020-01664-8>
28. Morrison SD, Capitán-Cañadas F, Sánchez-García A, et al. Prospective Quality-of-Life Outcomes after Facial Feminization Surgery: An International Multicenter Study. *Plast Reconstr Surg.* 2020;145(6):1499-1509. doi:10.1097/PRS.0000000000006837
29. Morrison SD, Vyas KS, Motakef S, et al. Facial Feminization: Systematic Review of the Literature. *Plastic & Reconstructive Surgery.* 2016;137(6):1759-1770. doi:10.1097/PRS.0000000000002171
30. Pansritum K. Forehead and Hairline Surgery for Gender Affirmation. *Plast Reconstr Surg Glob Open.* 2021;9(3):e3486. doi:10.1097/GOX.0000000000003486
31. Rosales O, Sejdiu Z, Camacho JM, et al. Facial feminization procedures and its impact on quality of life: A mini review. *Health Sciences Review.* 2023;7:100091. doi:10.1016/j.hsr.2023.100091
32. Salibian AA, Bluebond-Langner R. Lip Lift. *Facial Plastic Surgery Clinics of North America.* 2019;27(2):261-266. doi:10.1016/j.fsc.2019.01.004
33. Schmidt M, Ramelli E, Atlan M, Cristofari S. Étude anatomique scanographique du sinus frontal des patients transgenres en vue d'une chirurgie de frontoorbitoplastie de féminisation. *Annales de Chirurgie Plastique Esthétique.* 2023;68(2):93-98. doi:10.1016/j.anplas.2023.01.001
34. Somenek M. Gender-Related Facial Surgical Goals. *Facial Plast Surg.* 2018;34(5):474-479. doi:10.1055/s-0038-1670648
35. Spiegel JH. Facial determinants of female gender and feminizing forehead cranioplasty. *The Laryngoscope.* 2011;121(2):250-261. doi:10.1002/lary.21187
36. Swonke ML, Sturm A. Feminization of the midface: Cheek augmentation and buccal fat pad removal. *Operative Techniques in Otolaryngology-Head and Neck Surgery.* 2023;34(1):50-56. doi:10.1016/j.otot.2023.01.008
37. Sykes JM, Dilger AE, Sinclair A. Surgical Facial Esthetics for Gender Affirmation. *Dermatologic Clinics.* 2020;38(2):261-268. doi:10.1016/j.det.2019.10.011
38. Telang PS. Facial Feminization Surgery: A Review of 220 Consecutive Patients. *Indian J Plast Surg.* 2020;53(02):244-253. doi:10.1055/s-0040-1716440
39. Weinstein B, Alba B, Dorafshar A, Schechter L. Gender Facial Affirmation Surgery: Cheek Augmentation. *Facial Plastic Surgery Clinics of North America.* 2023;31(3):393-397. doi:10.1016/j.fsc.2023.04.002
40. Whitehead DM, Schechter LS. Cheek Augmentation Techniques. *Facial Plastic Surgery Clinics of North America.* 2019;27(2):199-206. doi:10.1016/j.fsc.2018.12.003
41. Wulu JA, Blasberg E, Spiegel JH. Feminizing frontal cranioplasty. *Operative Techniques in Otolaryngology-Head and Neck Surgery.* 2023;34(1):14-18. doi:10.1016/j.otot.2023.01.003